

Case Study #1

By Allyson Berent, DVM, DACVIM and Chick Weisse, VMD, DACVS
Department of Interventional Radiology/Endoscopy
The Animal Medical Center
New York, NY 10065

<http://www.amcny.org/interventional-radiology-endoscopy>

Allyson.Berent@amcny.org 212-329-8763

Chick.Weisse@amcny.org 212-329-8796

Signalment: 10 year old FS DSH

Presenting Complaint: Decreased appetite, vomiting, weight loss for approximately 2 weeks and one episode of hematuria.

Past pertinent history: Mild azotemia with creatinine between 2.5 and 3.1 for approximately 2 years.

Medications: K/D diet, famotidine (2.5 mg q 24 hrs)

Physical Examination: quiet and alert, BCS 4/9, renomegaly (right) and a left small kidney (approximately 2.5-3 cm). No pain on abdominal palpation

Diagnostic Evaluation:

CBC: mild normochromic normocytic nonregenerative anemia (24%)

Serum Biochemical Profile: BUN: 108 mg/dL, Creatinine 5.6 mg/dL, Phosphorus 12 mg/dL, Potassium: 4.7, Sodium 147

Urinalysis: USG: 1.015, no white blood cells, 10-20 red blood cells/hpf, no crystals, no bacteria seen, pH 6.5

Abdominal Radiographs: See figure 1

Abdominal Ultrasound: See figure 2

Urine culture: negative

Blood pressure: 130 mmHg systolic

Problem List:

- 1) Azotemia most likely chronic renal- and acute post-renal azotemia
- 2) Multiple ureterolithiasis and associated ureteral obstruction due to stone disease
- 3) Nephrolithiasis

Presumptive Diagnosis: Left Ureteral obstruction secondary to ureterolithiasis with associated chronic kidney disease (small right kidney and history of renal azotemia)

Treatment options:

- 1) Multiple ureterotomies
- 2) Ureteral re-implantation
- 3) Ureteral stenting

Treatment decisions:

Due to the mere number of stones in this patient's ureter and kidney traditional ureteral surgery was not considered the best option. The risk of surgery would entail serial ureterotomy procedures resulting in the risk of stricture, leakage and/or re-obstruction. Due to the fact that removal of all of the stones in the ureter would be impossible the chance for re-obstruction would be high. This led to the decision to place a ureteral stent inside the lumen of the ureter to bypass all of the stones without the need for stone removal. (**Figure 3**). This was accomplished with the combination of cystoscopy, fluoroscopy and abdominal surgery.

Outcome:

This patient was discharged from the hospital 4 days after ureteral stent placement with a creatinine of 3.1 mg/dL. She has been followed for the last 2 years with a radiograph, ultrasound, bloodwork and urine cultures every 3-6 months and her creatinine has been stable at 2.5 mg/dL with no evidence of renal pelvic dilation, no urinary tract infections and has been asymptomatic for here multiple ureteral and kidney stones.

Discussion:

Ureteral stenting can be performed for a variety of disorders to divert urine from the renal pelvis into the urinary bladder. This stent is a polyurethane-type of material that is very soft and biocompatible. It is an indwelling catheter that has a double pigtail shape allowing the proximal pigtail loop to curl inside the renal pelvis, the shaft travels through the entire ureteral lumen, with the distal loop sitting inside the urinary bladder. These loops prevent stent migration and allows the entire ureter to be protected from obstruction. This technique can be useful in patients with ureteral obstruction due to ureteral stones, ureteral or trigonal obstructive cancer, ureteral strictures/stenosis, for post-operative ureteral anastomosis/trauma, ureteral tears, ureteral spasm, or ureteral inflammation. In addition, the presence of the ureteral stent results in subsequent passive ureteral dilation, which can permit passage of previously obstructive ureterolith, or allow passage of urine around the stones and the stent. A feline ureter is normally 0.3-0.5 mm in diameter and after a ureteral stent is in place for a few days to approximately 2 weeks the diameter of the ureter can reach 1.5 mm in diameter. This technique is currently being performed in veterinary patients at The Animal Medical Center on a regular basis for various causes of ureteral obstruction like: ureterolith-induced obstructions, ureteral strictures, obstructive neoplasia and congenital ureteral anomalies. This is a very common procedure in the authors' practice as ureterolith induced obstructions in cats has become seemingly more common over the past 5-10 years and is a serious dilemma therapeutically. A feline ureteral stent has been created to fit more appropriately in a feline ureter, as the commercially available human stents are far too large for feline patients. Ureteral stenting is also ideal in patients with nephroliths or ureteroliths that are undergoing extracorporeal shockwave lithotripsy (ESWL) to aid in fragmentation and

passage of stone debris following treatment. To date approximately 170 ureteral stents have been placed in both dogs and cats for various causes and the longest stent remains indwelling for over 4 years.

IR/IE Tip:

Patients with newly diagnosed or worsening azotemia, and/or worsening urine specific gravity, further evaluation of the urinary system with radiologic imaging is highly recommended. Both abdominal radiographs and abdominal ultrasound are best when used in combination for the characterization of renal insufficiency, particularly for the diagnosis of ureteral obstruction(s). Stones can be missed on ultrasound and stone number, size, and location are often more obvious on radiographs. Ultrasound is ideal for documenting hydroureter and/or hydronephrosis which will aid in therapeutic planning.

***for more case examples and to see how interventional radiology and interventional endoscopy (IR/IE) can benefit your patients please see the following website:

<http://www.amcnny.org/interventional-radiology-endoscopy>

References: more available upon request

Berent A, Weisse C, Bagley D, Casale P. 2007. Ureteral stenting for benign and malignant disease in dogs and cats. Abstract presented at American College of Veterinary Surgery, 17-21 October, Chicago, IL.

Berent A, Weisse C, Bagley D, et al. Ureteral stenting for obstructive ureterolithiasis. Abstract, *American College of Veterinary Internal Medicine*, 2009, Montreal Canada.

Hubert KC. 2005. Passive dilation by ureteral stenting before ureteroscopy: eliminating the need for active dilation. *J Urol*. 174(3): 1079-1080.

Uthappa MC. 2005. Retrograde or antegrade double-pigtail stent placement for malignant ureteric obstruction? *Clinical Rad* 60: 608-612.

Figure 1. Lateral radiograph of patient. Notice that the left kidney is larger than the right and the multiple stones inside the left ureter ureter and both renal pelvis'.

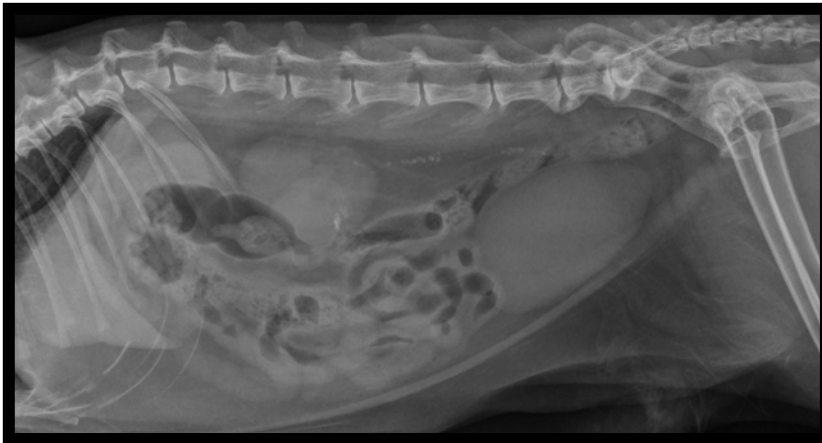

Figure 2. Abdominal ultrasound image of the left kidney documenting severe hydronephrosis (12 mm diameter) and hydroureter with multiple stones in the ureteral lumen that are shadowing.

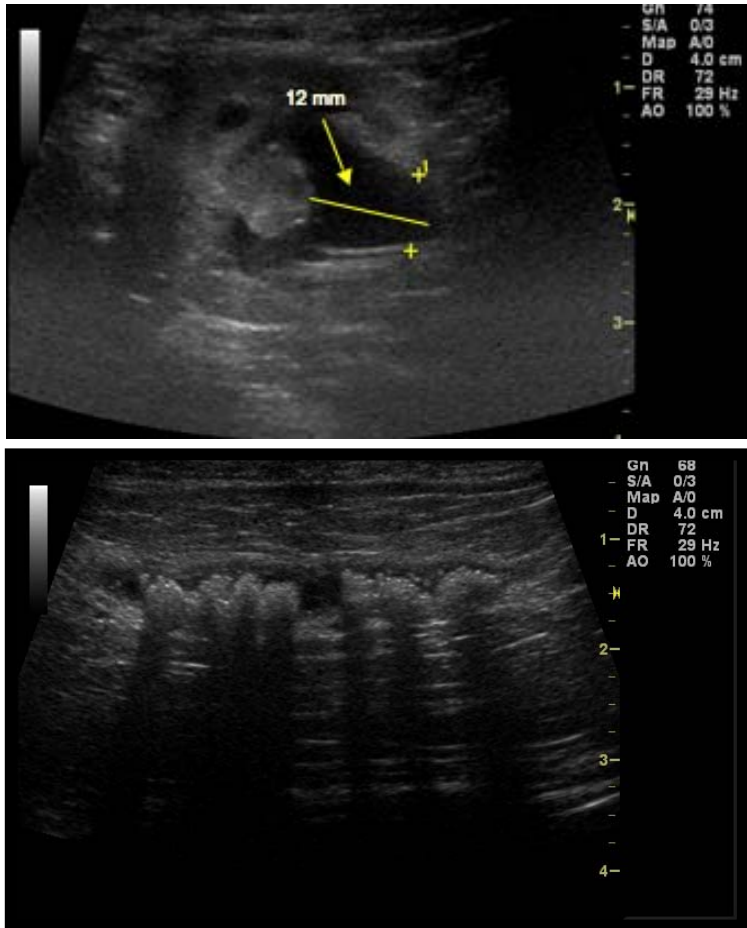


Figure 3. Fluoroscopy images during the ureteral stent placement. The first image is a retrograde ureteropyelogram. This was done via cystoscopy. A wire and catheter were advanced up the ureteral opening in side the urinary bladder and then using fluoroscopy contrast was used to image the ureter by a retrograde contrast ureterogram. Notice the numerous stones and filling defects inside the ureteral lumen and the dilated and tortuous ureter and dilated renal pelvis. The second image is of the patient with the ureteral stent in place. Notice the stent goes form the renal pelvis to the urinary bladder and the culrs inside the pelvis and bladder to prevent stent migration. Notice the contrast has drained from the kidney showing renal pelvis decompression with the ureteral stent.

